

Chauhan Nilesh Mukundbhai

Age:-24 years

Kukama-Bhuj-Kutch

In December 2004 I had sudden severe unbearable stomach pain. Then I used to get frequent such attacks. On prescription of allopathic doctor I got sonography report which was showing that I was having cirrhosis of liver, splenomegaly, ascitis and bilateral kidney stones. The allopathic treatment didn't give me any improvement, on the contrary my illness kept on increasing day by day. On March 2005 my endoscopy showed portal hypertension. On June 2005 Dr. went for my liver biopsy which showed chronic hepatitis (grade-2) with micro nodular cirrhosis (stage-4)

On July 2005 I started Ayurvedic treatment from Dr. Amina Khatri. With her regular treatment my disease started getting cured, swellings from my body parts started decreasing, fever stopped. My liver reports started improving

Until June 2007 I took regular treatment from Dr. Amina Khatri my blood reports of liver became normal and liver sonography was almost normal, spleen was a bit enlarged.

After that I take her medicine irregularly (one dose sometimes). In 2008 my reports were even better than 2007 ones, and reports conducted in 2010 are even match better than the previous ones.

I live a healthy, routine life now!!!

Thanks to Dr. Amina Khatri.



Nilesh M. Chauhan.

DR. AMINA'S

# +ROYAL AYURVEDA+

PURE AYURVEDIC TREATMENT

Dr. Amina M. Khatri  
(B.A.M.S.)  
Mobile: - 098259 64736 / 094272 35572  
Email : - draminakhatr@gmail.com  
visit us : [www.royalayurveda.com](http://www.royalayurveda.com)

Beena Tower 3rd Floor,  
Near Hotel Rartrani, Station Road,  
Bhuj-Kutch,  
Gujarat, Pin-370001. (India)

Date :- 26/6/2010

ચૌહાણ નિલેશ મુકુંદભાઈ

ઉંમર વર્ષ : 28

ગામ : કુડમાલ- ઉચ્છતા: ભુજ.

મને ડિસેમ્બર 2008 માં અચાનક પેટમાં ભયંકર દુ:ખનો ધવો. પછી અવર-નવર દુ:ખાવો થવા લાગ્યો. એસોપઈ ડૉક્ટર પાસે નિહાળ કરાવવા ગયો તો સોનોગ્રાફી કરાવતાં અવર પડી કે લીવર-સીરોસીસ - સ્પ્લીન મેથાસી, એસાઇટીસ અને હીડનીમાં પથરી પડેલી. હવા ચાલું કરી હતા બીમારી દિવસ-દિવસ વધવા લાગી મારે 2009 માર્ચમાં હોસ્પિટીમાં કરાવતાં ચોર્ટીસ ડ્રાઇપરેન્જરનું નું નિહાળ આપ્યું. જુન 2009 માં ડૉક્ટરે લિવરની બાયોપસી કરાવી. તેમાં લિપોસાઇટીસ ગ્રેડ-2 તથા સીરોસીસ ગ્રેડ-૪ આપ્યું.

જુલાઈ 2009 માં મેં ડૉ. અમીનાબેન ખત્રીની આયુર્વેદિક દવા શરૂ કરી. તેમની નિયમિત સારવારથી મારી બિમારીમાં સુધારો થયો. શરીર પરનું શોષન બેસી ગયા, તાવ મટી ગયો, લીવરનું રીપોર્ટ સુધરવા લાગ્યું.

મેં જુન 2009 સુધી ડૉ. અમીનાબેન ખત્રીની દવા નિયમિત ખાધી. મારી બધી જ બિમારી મટી ગઈ. મારું લીવરનું તથા લોહીનું રીપોર્ટ નોર્મલ થઈ ગયા. અને લીવર સોનોગ્રાફીમાં અલ્ટ્રાસાઉન્ડ નોર્મલ થઈ ગઈ અને સ્પ્લીન ઘોડી મોટી હતી.

તે પછી હું એમની દવા અનિયમિત રીતે ડ્યારેક એક ડોઝ ખાતો છું.

મારા 2009 ના રિપોર્ટ કરતાં 2008 ના - રીપોર્ટ સુધરેલા છે. અને 2010 ના હાલના રિપોર્ટ એમના કરતાં પણ ઘણા સારા આવે છે. હું નિયમિત સેન્ટ્રલ જીવન જીવું છું. તંદુરસ્ત છું. વનવાદ : ડૉ. અમીનાબેન ખત્રી,

નિલેશ એન વ્યોમજી.



# NAVKAR

## X-RAY & SONOGRAPHY CLINIC

22, Vijaynagar, Opp. G.E.B., Near Goldan Palace,  
Bhuji (Kachchh) - 370 001.  
Ph.: (C) 252190, 224726 (R) 226650, 309865

**Dr. Jigar C. Salvi**

M.D., D.M.R.E. (Radiology)  
Consultant Radiologist & Sonologist

**Dr. Archana J. Salvi**

M.D., D.M.R.E. (Radiology)  
Consultant Radiologist & Sonologist

NILESH CHAUHAN  
19 Years Male  
DR. K. D. VEGAD M.S.  
18/12/2004

### ABDOMINAL SONOSCREENING (M)

**LIVER:** appears normal in size, shows coarse echopattern. No focal mass lesion seen. No dilated IHBR seen. CBD appears normal in size. Portal vein measuring 14 mm.

**SPLEEN:** is enlarged, appears normal in echopattern. No focal mass lesion seen. Splenic vein measures 9.5 mm.

**GALL BLADDER:** shows physiological wall oedema. No calculus or mass lesion seen.

**PANCREAS:** appears normal in size and echopattern. No evidence of focal mass lesion or changes of pancreatitis seen.

**BOTH KIDNEYS:** appears normal in size and echopattern. No evidence of hydronephrosis or mass lesion seen involving either kidney. There are 3 mm size two calculi seen in upper and middle calyx of right kidney. There are 3 mm size two calculi seen in upper and middle calyx of left kidney and 3 mm size one calculus seen in lower calyx of left kidney.

RK: 10.55 X 4.43 cm. LK: 10.78 X 5.76 cm.

No lymphadenopathy seen. Mild degree ascites seen.

**URINARY BLADDER:** appears normal. No evidence of calculus or mass lesion seen.

**PROSTATE:** appears normal in size and echopattern.

**COMMENT :** COARSE ECHOPATTERN OF LIVER ?  
CIRRHOSIS, SPLENOMEGALY, ASCITES, BILATERAL RENAL CALCULI.

**ADVISE:** Clinical co-relation and further investigation.





# NAV KAR COLOR DOPPLER CENTRE

22, Vijaynagar, Opp. G.E.B., Near Goldan Palace, Bhuj (Kachchh) - 370 001.  
Ph.: (C) 252190, 224726 (R) 226650, 309865

**Dr. Jigar C. Salvi**

M.D., D.M.R.E. (Radiology)  
Consultant Radiologist & Sonologist

**Dr. Archana J. Salvi**

M.D., D.M.R.E. (Radiology)  
Consultant Radiologist & Sonologist

NILESH CHAUHAN  
19 Years Male  
DR. K. D. VEGAD M.S.

14/02/2005

## ABDOMINAL SONOSCREENING (M)

LIVER: appears normal in size, shows coarse echopattern. No focal mass lesion seen. No dilated IHBR seen. CBD appears normal in size. PV measuring 1.43 cm.

SPLEEN: is enlarged appears normal in echopattern. No focal mass lesion seen. SV measuring 1.03 cm.

GALL BLADDER: shows physiological wall oedema. No calculus or mass lesion is seen.

PANCREAS: appears normal in size and echopattern. No evidence of focal mass lesion or changes of pancreatitis seen.

BOTH KIDNEYS: appears normal in size and echopattern. No evidence of mass lesion seen involving either kidney. There is 3 mm size calculus seen in upper, middle and lower calyx of both kidney. Mild degree hydronephrosis seen on right side. There is 4 mm size right VUJ calculus seen.

RK: 11.15 X 5.07 cm. LK: 10.61 X 4.29 cm.

No ascites or lymphadenopathy seen.

URINARY BLADDER: appears normal. No evidence of calculus or mass lesion seen.

PROSTATE: appears normal in size and echopattern.

COMMENT: ? CIRRHOSIS OF LIVER. SPLENOMEGALY. PHYSIOLOGICAL GALL BLADDER WALL OEDEMA. BILATERAL RENAL CALCULI. RIGHT VASICOURETERIC JUNCTION CALCULUS.

ADVISE: Clinical co-relation and further investigation.

Thanks For Ref.

**DR. K. K. RAWAL.** M.D. (MED) D.M. (GASTRO)  
**GASTRO AND LIVER DISEASE HOSPITAL.**  
**VIDYANAGAR MAIN ROAD, RAJKOT.**

Name : NILESHBHAI

Age/Sex : 18 / Male

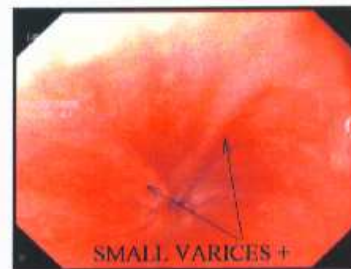
ID : 93057

Ref. By DR. A. SHAH. DR. K. VAGAD

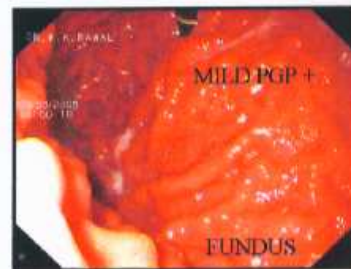9-Mar-2005

**Upper GI Endoscopy Report**

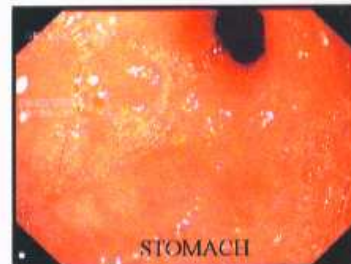**Mucosa :** Esophageal Varices GR-1-2 Column.  
*(after Valsalva)*  
**Hiatus Hernia :** Absent  
**OG - Jn. :** 40 cm **ESOPHAGUS**  
**GE Reflux :** Absent



**Cardia :** Normal  
**Fundus :** Mild PGP +  
**Body :** Normal **STOMACH**  
**Antrum :** Normal  
**Pylorus :** Normal



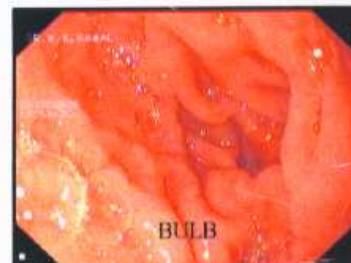**1st Part :** Normal  
**2nd Part :** Normal **DUODENUM**  
**Ampula :** Normal



**Biopsy :** Not Taken

**Final Impression :**

**PORTAL HYPERTENTION**



DR. K. K. RAWAL.

4

Phone : 2646 6365, 2640 1178  
Fax No.: 2640 1178

# HISTOPATHOLOGY and CYTOLOGY CLINIC

302, ABHIGAM COMPLEX, 3RD FLOOR, OPP. DOCTOR HOUSE, C. G. ROAD,  
ELLISBRIDGE, AHMEDABAD-380 006.

**DR. UNITA K. SHAH**  
M.D. (Pathology) U.S.A.



**DR. BHARATI N. PARIKH**  
M.D. (Pathology) U.S.A.

Patient's Name : Nitesh Chauhan  
Age : 18 Yrs  
Referred by : Dr. Bhatnagar Manish S.

Date : 18/06/2005

HPC No. 5088/2005

## HISTOLOGY REPORT

Specimen : Liver biopsy.

Gross : Specimen consists of one cylindrical fragment of tissue measuring 1.7 cm. All taken.

Micro. : Sections reveal effaced hepatic architecture with portal fibrosis, lymphocytic, eosinophilic and plasmacell infiltrate and micronodule formation. Piecemeal necrosis is present. Focal bile duct proliferation is evident. Mallory-hyaline bodies, degenerated hepatocytes are present.

Diagnosis : Chronic hepatitis (grade 2) with micronodular cirrhosis (stage 4).

THE SLIDE(S) AND BLOCK(S) ARE ISSUED WITH THIS REPORT.  
PLEASE PRESERVE CAREFULLY.

*U.K.S.*

(Dr. U.K.Shah)

*U.K.S.  
B.N.P.*

(Dr. B.N.Parikh)

SPECIMENS ARE ACCEPTED BETWEEN 9 A.M. TO 8 P.M.



5



# VISHWAS PATHOLOGICAL LABORATORY

LAB : First Floor, " Doctor House ", Opp. G. K. General Hospital, BHUJ - KUTCH. Ph. : (02832) 253776

RESI. : First Floor, Satyam Tower, Vijaynagar, Hospital Road, BHUJ - KUTCH. Ph. (02832) 250736

*Dipak K. Trivedi*

B.Sc. [MICRO], C.M.L.T.

COMPUTERIZED UNIT  
24 HOURS SERVICE

PATIENT NAME : NILESH CHAUHAN  
AGE & SEX : 19 years, MALE  
REFERRING DR. : DR. ASHOK HINDUJA, M.D. (MEDICINE)

DATE : 13/06/2005

REF.NO: 38952

## PROTHROMBINE TIME REPORT

[ NORMAL VALUES ]

Prothrombine Time : ( Quick's One Stage Method )

PATIENT : 23.2 Seconds. 10 - 15 Seconds  
CONTROL : 12.3 Seconds.

Prothrombin Index : 53 % 70 - 110 %

Prothrombin Ratio : 1.89

Remark : I.N.R. : 2.02



*Dipak*  
For, Vishwas Path. Lab.

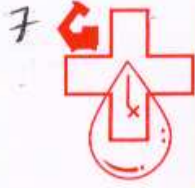Regd. No. : F/459/jnd, L.M.No. : T / 008 / Bhuj

The test results are Subjected to variation due to technical limitations hence correlation with clinical findings & other investigations should be carried out

PLEDGE YOUR EYES







**DR. TANNA**  
**LABORATORY**

(PATH. & MICRO)

Shop No. -7, Santosh Towers, Vijaynagar, Nr. Bhuj English School, Behind Rotary Hall, BHUJ. P.N. : 370001. Phone:(L)258147,309747(R)254900

**Dr. Dinesh Tanna**

M.D. (Pathology) D.C.P.

Name : NILESHBHAI CHAUHAN Age : 18Years  
Ref. by : DR. AMINABEN KHATRI/DR. MOHD. SALIM KHATRI Sex : Male  
Ref. No. : 5 Date : 02/07/05

**LIVER FUNCTION TEST**

<u>TEST</u>	<u>RESULTS</u>	<u>NORMAL VALUES</u>
S.G.P.T. (ALT) [Kinetic] (RAICHEM-U.S.A.)	: 196 U/L	8 to 42 U/L AT 37 °C

EXTENDED HRS. LAB. : OPEN FROM MORNING 8.00 A.M. TO NIGHT 11.00 P.M.  
( SUNDAY MORNING FROM 8.00 TO 2.00 NOON)

NEWER TESTS : 1) T3, T4, TSH BY RIA METHOD, 3) CULTURE FOR TYPHOID FEVER.  
2) BLOOD CULTURE, 4) GLYCOSYLATED HB(HBA1C)

Thanks for Reference

RECOGNISED BY L.I.C. OF INDIA

Pathologist

**Note** : The above results are subject to variations due to technical limitations. Hence correlation with Clinical findings and other Investigations should be done.

Laboratory Medicine Cell ડાહ્યા પ્રમાણિત લેલોરેટરી



**DR. TANNA**  
**LABORATORY** (PATH. & MICRO)

Shop No. -7, Santosh Towers, Vijaynagar, Nr. Bhuj English School, Behind Rotary Hall, BHUJ. P.N. : 370001. Phone:(L)258147,309747(R)254900  
Dr. Dinesh Tanna  
M.D. (Pathology) D.C.P.

Name : NILESHBHAI CHAUHAN Age : 18Years  
Ref. by : DR. AMINABEN KHTRIMADAM Sex : Male  
Ref. No. : 4 Date : 15/07/05

**RENAL PROFILE**

TEST	RESULTS	NORMAL
1. BLOOD UREA	: 46.6 mg/dl	15 - 40 mg/dl
2. B.U.N.	: mg/dl	8 - 23 mg/dl
3. SR. CREATININE	: 1.54 mg/dl	0.9 - 1.4 mg/dl -M 0.8 - 1.2 mg/dl -F
4. TOTAL PROTEIN	: gm/dl	6 - 7.8 gm/dl
5. Sr. ALBUMIN	: gm/dl	3.2 - 4.5 gm/dl
6. Sr. GLOBULIN	: gm/dl	2.3 - 3.5 gm/dl
7. A.G. RATIO	:	

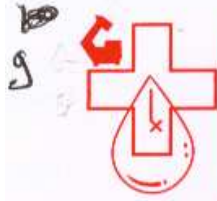**PATHOLOGIST**

EXTENDED HRS. LAB. : OPEN FROM MORNING 8.00 A.M. TO NIGHT 11.00 P.M.  
( SUNDAY MORNING FROM 8.00 TO 2.00 NOON)  
NEWER TESTS : 1) T3, T4, TSH BY RIA METHOD, 3) CULTURE FOR TYPHOID FEVER,  
2) BLOOD CULTURE, 4) GLYCOSYLATED HB (HBA1C)

Thanks for Reference      **RECOGNISED BY L.I.C. OF INDIA**      Pathologist

**Note** : The above results are subject to variations due to technical limitations. Hence correlation with Clinical findings and other Investigations should be done.

**Laboratory Medicine Cell** હારા પ્રમાણિત લેબોરેટરી



**DR. TANNA**  
**LABORATORY** (PATH. & MICRO)

Shop No. -7, Santosh Towers, Vijaynagar, Nr. Bhuj English School, Behind Rotary Hall, BHUJ. P.N. : 370001. Phone:(L)258147,309747(R)254900  
Dr. Dinesh Tanna  
M.D. (Pathology) D.C.P.

Name : NILESHBHAI CHAUHAN Age : 18Years  
Ref. by : DR. AMINABEN KHTRIMADAM Sex : Male  
Ref. No. : 4 Date : 15/07/05

**LIVER FUNCTION TEST**

<u>TEST</u>	<u>RESULTS</u>	<u>NORMAL VALUES</u>
S.G.P.T. (ALT) [Kinetic]( RAICHEM-U.S.A.)	: 185 U/L	8 to 42 U/L AT 37 °C

EXTENDED HRS. LAB. : OPEN FROM MORNING 8.00 A.M. TO NIGHT 11.00 P.M.  
( SUNDAY MORNING FROM 8.00 TO 2.00 NOON)  
NEWER TESTS : 1) T3, T4, TSH BY RIA METHOD, 3) CULTURE FOR TYPHOID FEVER.  
2) BLOOD CULTURE, 4) GLYCOSYLATED HB(HBA1C)

Thanks for Reference      **RECOGNISED BY L.I.C. OF INDIA**      Pathologist  
**Note** : The above results are subject to variations due to technical limitations. Hence correlation with Clinical findings and other investigations should be done.  
**Laboratory Medicine Cell द्वारा प्रमाणात लेबोरेटरी**





**DR. TANNA**  
**LABORATORY**

(PATH. & MICRO)

Shop No. -7, Santosh Towers, Vijaynagar, Nr. Bhuj English School, Behind Rotary Hall, BHUJ. P.N. : 370001. Phone:(L)258147,309747(R)254900  
**Dr. Dinesh Tanna**  
M.D. (Pathology) D.C.P.

Name : NILESHBHAI CHAUHAN Age : 18 Years  
Ref. by : DR. AMINABEN KHATRIMADAM Sex : Male  
Ref. No. : 7 Date : 01/08/05

**LIVER FUNCTION TEST**

<u>TEST</u>	<u>RESULTS</u>	<u>NORMAL VALUES</u>
S.G.P.T. (ALT) [Kinetic] (RAICHEM-U.S.A.)	: 180 U/L	8 to 42 U/L AT 37 °C

EXTENDED HRS. LAB. : OPEN FROM MORNING 8.00 A.M. TO NIGHT 11.00 P.M.  
( SUNDAY MORNING FROM 8.00 TO 2.00 NOON)

NEWER TESTS : 1) T3, T4, TSH BY RIA METHOD, 3) CULTURE FOR TYPHOID FEVER.  
2) BLOOD CULTURE, 4) GLYCOSYLATED HB (HBA1C)

Thanks for Reference

RECOGNISED BY L.I.C. OF INDIA

Pathologist

**Note** : The above results are subject to variations due to technical limitations. Hence correlation with Clinical findings and other investigations should be done.

Laboratory Medicine Cell ૧૨૧ ૧૧૧૧૧૧ ૧૧૧૧૧૧











**DR. TANNA**  
**LABORATORY** (PATH. & MICRO)

Shop No. -7, Santosh Towers, Vijaynagar, Nr. Bhuj English School, Behind Rotary Hall, BHUJ. P.N. : 370001. Phone:(L)258147,309747(R)254900  
**Dr. Dinesh Tanna**  
 M.D. (Pathology) D.C.P.

Name : NILESHBHAI CHAUDHAN Age : 18 Years  
 Ref. by : DR. AMINABEN KATRIMADAM Sex : Male  
 Ref. No. : 5 Date : 01/10/05

#####  
 3 LIVER FUNCTION TEST 3  
 #####

TEST	RESULTS	NORMAL VALUES
S.G.P.T. (ALT) (Kinetic) ( RAICHEM-U.S.A.)	: 32 U/L	8 to 42 U/L AT 37 °C

Remarks :

EXTENDED HRS. LAB. : OPEN FROM MORNING 8.00 A.M. TO NIGHT 11.00 P.M.  
 ( SUNDAY MORNING FROM 8.00 TO 2.00 NOON)  
 NEWER TESTS : 1) T3, T4, TSH BY RIA METHOD, 3) CULTURE FOR TYPHOID FEVER.  
 2) BLOOD CULTURE, 4) GLYCOSYLATED HB (HBA1C)

Thanks for Reference      **RECOGNISED BY L.I.C. OF INDIA**      Pathologist

**Note** : The above results are subject to variations due to technical limitations. Hence correlation with Clinical findings and other Investigations should be done.

**Laboratory Medicine Cell** હાલ પ્રમાણિત લેબોરેટરી

15

# Dr. B. R. PANDYA LABORATORY

## PATHOLOGY & CLINICAL LABORATORY

*Dr. B. R. Pandya*

M.D., (Path & Bact) D.C.P.

Consultant Pathologist



Hospital Road  
BHJJ-Kutch. 370 001  
Tel.: 02832 - 250066

PATIENT NAME : NILESH CHAUHAN  
AGE & SEX : 18 years, MALE  
REFERRING DR. :

DATE : 01/11/2005  
REF.NO: 23174

### SERUM BILIRUBIN & SGPT

S. Bilirubin :		[ NORMAL VALUES ]
Total	: Mg %	0.15 - 1.2 Mg %
Direct	: Mg %	Upto 0.3 Mg %
Indirect	: Mg %	0.1 - 1.0 Mg %
S.G.P.T.	: 53 I.U./Lit.	5 - 40 I.U./Lit.

REMARK : report suggests high SGPT level.

  
DR. B. R. PANDYA



20-16

**Dr. B. R. PANDYA LABORATORY**  
**PATHOLOGY & CLINICAL LABORATORY**

*Dr. B. R. Pandya*

M.D., (Path & Bact) D.C.P.

**Consultant Pathologist**



DR. B. R. PANDYA

Hospital Road

BHUL Kutch. 370 001

Tel.: 02832 - 250066

PATIENT NAME : NILESH CHAUHAN  
AGE & SEX : 18 years, MALE  
REFERRING DR. :

DATE : 01/11/2005  
REF.NO: 23174

**BLOOD UREA & SERUM CREATININE**

Blood Urea : 29.1 Mg %

[ NORMAL VALUES ]  
15 - 50 Mg %

Serum Creatinine : 1.23 Mg %

0.6-1.4 MG/DL

  
DR. B. R. PANDYA



SHRI KUTCHI LEVA PATEL EDUCATION & MEDICAL TRUST  
SANCHALIT

**MATRUSHRI MEGHBAI PREMJI JETHA HOSPITAL & RESEARCH CENTRE**

Patient Name : Nilesh Mukund Chauhan CR Numbe : 0003870  
Sex & Age : Male 19 yrs 6 mths Reg.Code : 20051202075  
Doctor : *Anita Chauhan* Reg.Type : OPD

Date : 02/Dec/2005

**SONOGRAPHY ABDOMEN WITH PELVIS**

**LIVER :**

is minimally reduced in size (14 cms) and shows diffuse altered echotexture (course echotexture). No evidence of focal mass lesion seen.  
No evidence of dilated IHBR. PV and CBD appear normal in calibre.

**GALL BLADDER :**

Appears normal. No evidence of stone or cholecystitis seen.

**PANCREAS :**

Appears normal in size and echotexture. No focal mass lesion or changes of pancreatitis seen.

**SPLEEN :**

shows mild enlargement (13 cms) and shows normal echotexture.  
No evidence of focal lesion.

**BOTH KIDNEYS :**

Appear normal in size and echotexture with preservation of corticomedullary differentiation.  
No evidence of hydronephrosis or mass lesion involving either kidney.  
4 mm calculus in lower calyx of right kidney.

**URINARY BLADDER :**

appears normal. No intrinsic lesion seen.

**PROSTATE :**

normal in size and echotexture.

No evidence of ascites seen. Para-aortic region is obscured by bowel gas.


**CONCLUSION :**

- \* Liver shows altered echotexture, no focal mass lesion seen.  
P/O Liver parenchymal disease. Adv: Biopsy.
- \* Mild splenomegaly. \* Small rt renal calculus, no hydronephrosis.

No ascites seen.

**Advise:** Clinical co-relation and further investigation.

Dr. Harshad Patel  
M. D., D. M. R. E.  
Radiologist

  
Dr. Darshan Bosamia  
M. D., D. M. R. E.  
Radiologist

28



SHRI KUTCHI LEVA PATEL EDUCATION & MEDICAL TRUST  
SANCHALIT

**MATRUSHRI MEGHBAI PREMJI JETHA HOSPITAL & RESEARCH CENTRE**

Patient Name : Nilesh Mukund Chauhan  
Sex & Age : Male 19 yrs 9 mnths  
Ref.Doctor : Amina Khatri

CR Number : 0003870  
Reg.Code : 20060301071  
Reg.Type : OPD  
Date : 01/Mar/2006

Test	Result	Normal Range	Test Method
<b>S G P T</b>			
<b>S G P T</b>	<b>50.30</b> IU/L	↑ 0 - 40	IU/L IFCC METHOD

*Dr. Navin R Patel*  
Pathologist

↑↑↑ - PanicHigh   ↑↑ - AlertHigh   ↑ - AbnormalHigh   ↓ - Abnormal Low   ↓↓ - AlertLow   ↓↓↓ - PanicLow

49



**SHRI KUTCHI LEVA PATEL EDUCATION & MEDICAL TRUST  
SANCHALIT**

**MATRUSHRI MEGHBAI PREMJI JETHA HOSPITAL & RESEARCH CENTRE**

**Patient Name** : Nilesh Mukund Chauhan  
**Sex & Age** : Male 20 yrs  
**Ref.Doctor** : Amina Khatri

**CR Number** : 0003870  
**Reg.Code** : 20060415071  
**Reg.Type** : OPD  
**Date** : 15/Apr/2006

Test	Result	Normal Range	Test Method
<b>SGPT</b>			
<b>SGPT</b>	<b>32.30</b> IU/L	0 - 40	IU/L IFCC METHOD

*Dr. Navin R Patel*  
**Dr. Navin R Patel**  
**Pathologist**

↑↑↑ - PanicHigh    ↑↑ - AlertHigh    ↑ - AbnormalHigh    ↓ - Abnormal Low    ↓↓ - AlertLow    ↓↓↓ - PanicLow





SHRI KUTCHI LEVA PATEL EDUCATION & MEDICAL TRUST  
SANCHALIT

**MATRUSHRI MEGHBAI PREMJI JETHA HOSPITAL & RESEARCH CENTRE**

Patient Name : Nilesh Mukund Chauhan  
Sex & Age : Male 20 yrs 1 mnths  
Ref.Doctor : Amina Khatri

CR Number : 0003870  
Reg.Code : 20060515064  
Reg.Type : OPD  
Date : 15/May/2006

Test	Result	Normal Range	Test Method
------	--------	--------------	-------------

**BLOOD UREA & S.CREATININE**

<b>BLOOD UREA</b>	<b>19.30</b>	mg/dL	19 - 43	mg/dL	GLDH-UREASE METHOD
<b>S. CREATININE</b>	<b>1.40</b>	mg/dL	0.60 - 1.40	mg/dL	MODIFIED JAFFE'S METHOD

Remarks : \* RECHECKED.

**PROTHROMBIN TIME**

**PROTHROMBIN TIME**

CONTROL	<b>14.10</b>	Seconds			LIQUID THROMBOPLASTIN METHOD
TEST	<b>25.00</b>	Seconds	10 - 20	Seconds	By Coag Uno Automated-TRANSASIA
<b>PROTHROMBIN INDEX</b>	<b>56.40</b>	%	70 - 100	%	
T/C RATIO	<b>1.773</b>	.			
INR	<b>1.800</b>	.			

**S G P T**

<b>S G P T</b>	<b>38.00</b>	IU/L	0 - 40	IU/L	IFCC METHOD
----------------	--------------	------	--------	------	-------------

  
Dr. Navin R. Patel  
Pathologist

↑↑↑ - PanicHigh    ↑↑ - AlertHigh    ↑ - AbnormalHigh    ↓ - Abnormal Low    ↓↓ - AlertLow    ↓↓↓ - PanicLow

21



SHRI KUTCHI LEVA PATEL EDUCATION & MEDICAL TRUST  
SANCHALIT

**MATRUSHRI MEGHBAI PREMJI JETHA HOSPITAL & RESEARCH CENTRE**

SARDAR PATEL VIDYA SANKUL, BHUJ - MUNDRA ROAD, BHUJ-KUTCH. 370 001 TEL. : (02832) 231133, 231144

<b>Patient Name</b> : Nilesh Mukund Chauhan	<b>CR Number</b> : 0003870
<b>Sex &amp; Age</b> : Male 20 yrs 6 mnths	<b>Reg.Code</b> : 20061114152
<b>Ref.Doctor</b> : Amina Khatri	<b>Reg.Type</b> : OPD
	<b>Date</b> : 14/Nov/2006

Test	Result	Normal Range	Test Method
<b>PROTHROMBIN TIME</b>			
<b>PROTHROMBIN TIME</b>			
CONTROL	<b>13.20</b> Seconds		LIQUID THROMBOPLASTIN METHOD
TEST	<b>16.40</b> Seconds	10 - 20 Seconds	By Coag Uno Automated-TRANSASIA
<b>PROTHROMBIN INDEX</b>	<b>80.49</b> %	70 - 100 %	
T/C RATIO	<b>1.242</b> .		
INR	<b>1.200</b> .		
<b>S G P T</b>			
<b>S G P T</b>	<b>33.90</b> IU/L	0 - 40 IU/L	IFCC METHOD

Checked By : *SVV*

*Navin Patel*  
**Dr. Navin Patel**  
**Pathologist**

↑↑↑ - PanicHigh    ↑↑ - AlertHigh    ↑ - AbnormalHigh    ↓ - Abnormal Low    ↓↓ - AlertLow    ↓↓↓ - PanicLow



SHRI KUTCHI LEVA PATEL EDUCATION & MEDICAL TRUST  
SANCHALIT

**MATRUSHRI MEGHBAI PREMJI JETHA HOSPITAL & RESEARCH CENTRE**

SARDAR PATEL VIDYA SANKUL, BHUJ - MUNDRA ROAD, BHUJ-KUTCH. 370 001 TEL. : (02832) 231133, 231144

Patient Name : Nilesh Mukund Chauhan  
Sex & Age : Male 21 yrs 2 mnths  
Ref.Doctor : Amina Khatri

CR Number : 0003870  
Reg.Code : 20070630091  
Reg.Type : OPD  
Date : 30/Jun/2007

Test	Result	Normal Range	Test Method
------	--------	--------------	-------------

**PROTHROMBIN TIME**

**PROTHROMBIN TIME**

Test	Result	Normal Range	Test Method
CONTROL	13.60 Seconds		LIQUID THROMBOPLASTIN METHOD
TEST	15.10 Seconds	10 - 20 Seconds	By Coag Uno Automated-TRANSASIA
PROTHROMBIN INDEX	90.07 %	70 - 100 %	
T/C RATIO	1.110		
INR	1.000		

Checked By :

Dr. Navin Patel (D.C.P., M.D. (PATHO))  
Pathologist

↑↑↑ - PanicHigh    ↑↑ - AlertHigh    ↑ - AbnormalHigh    ↓ - Abnormal Low    ↓↓ - AlertLow    ↓↓↓ - PanicLow



**SHRI KUTCHI LEVA PATEL EDUCATION & MEDICAL TRUST**  
**SANCHALIT**

**MATRUSHRI MEGHBAI PREMJI JETHA HOSPITAL & RESEARCH CENTRE**

SARDAR PATEL VIDYA SANKUL, BHUJ - MUNDRA ROAD, BHUJ-KUTCH. 370 001 TEL. : (02832) 231133, 231144

**Patient Name :** Nilesh Mukund Chauhan  
**Sex & Age :** Male 21 yrs 2 mths  
**Doctor :** Amina Khatri

**CR Numbe :** 0003870  
**Reg.Code :** 20070630102  
**Reg.Type :** OPD

Date : 30/Jun/2007

**SONOGRAPHY ABDOMEN WITH PELVIS**

**LIVER :**

Appears normal in size ( liver span measuring: 15.78 cm ) and diffuse coarsening of liver echotexture seen on either lobe of liver, No evidence of dilated IHBR. PV and CBD appear normal in calibre.

On Colour doppler examination, Portal vein appears normal. Right and left branch of Portal vein normal. No e/o thrombosis seen. Hepatic veins and its branches appears normal. No e/o thrombosis seen.

Liver contour appears normal. No e/o crenated margin seen.

**GALL BLADDER :**

Appears normal. No evidence of stone or cholecystitis seen.

**PANCREAS :**

Appears normal in echotexture and size. No e/o Pancreatitis seen.

**SPLEEN :**

Appears borderline increased in size ( splenic span measuring: 13.62 cm ), No e/o focal lesion seen.

**BOTH KIDNEYS :**

Appear normal in size and echotexture with preservation of corticomedullary differentiation. No evidence of calculus, hydronephrosis or mass lesion involving either kidney.

RK:9.9 x 4.0 cm LK:11.1 x 4.2 cm

**URINARY BLADDER :**

appears normal. No intrinsic lesion seen.

**PROSTATE :**

normal in size and echotexture.

No evidence of ascites or paraaortic lymphadenopathy.

**CONCLUSION :**

**Finding suggestive of**

- \* Liver shows diffuse coarsening of echotexture,
- \* No e/o Ascites seen.
- \* Borderline Splenomegaly seen.

**Advise:** Clinical co-relation and further investigation.

Dr. Kripalsinh N Jadeja  
M.B., D.M.R.E.  
Radiologist





SHRI KUTCHI LEVA PATEL EDUCATION & MEDICAL TRUST  
SANCHALIT

**MATRUSHRI MEGHBAI PREMJI JETHA HOSPITAL & RESEARCH CENTRE**

SARDAR PATEL VIDYA SANKUL, BHUJ - MUNDRA ROAD, BHUJ-KUTCH. 370 001 TEL.: (02832) 231133, 231144

Patient Name : Nitesh Mukund Chauhan  
Sex & Age : Male 22 year 2 months  
Ref.Doctor : Amina Khatri

CR Number : 0003870  
Reg.Code : 20080623168  
Reg.Type : OPD  
Date : 23/Jun/2008

Test	Result	Normal Range	Test Method
<b>PROTHROMBIN TIME</b>			
<b>PROTHROMBIN TIME</b>			
CONTROL	13.80	Seconds	LIQUID THROMBOPLASTIN METHOD By Coag Uno Automated-TRANSASIA
TEST	15.20	Seconds	
PROTHROMBIN INDEX	90.79	%	70 - 100 %
T/C RATIO	1.101	.	
INR	1.100	.	

Checked By :

Dr. Navin Patel (D.C.P., M.D. (PATHO))  
Pathologist

↑↑↑ - PanicHigh    ↑↑ - AlertHigh    ↑ - AbnormalHigh    ↓ - Abnormal Low    ↓↓ - AlertLow    ↓↓↓ - PanicLow

25

# SHRI SWAMINARAYAN X-RAY & ULTRASOUND CLINIC

## શ્રી સ્વામિનારાયણ એક્સ-રે એન્ડ અલ્ટ્રાસાઉન્ડ ક્લિનિક

**Dr. Krishnakant S. Vaghela**

M.B.B.S., M.D. (Radiology) D.M.R.E.

**Dr. Jayshree K. Vaghela**

(B.A.M.S.)

Consultant Radiologist Sonologist



**ડૉ. કૃષ્ણકાંત એસ. વાઘેલા**

એમ.બી.બી.એસ., એમ.ડી. (રેડિયોલોજી)

**ડૉ. જયશ્રી કે. વાઘેલા**

(બી.એ.એમ.એસ.)

એક્સ-રે અને સોનોગ્રાફીના નિષ્ણાંત

Dr. Aminaben Khatri (B.A.M.S.)

Abdo Pelvic sono exam ..... Sept 6, 2008

Liver :-

ECHO-TEXTURE OF LIVER APPEARS NORMAL but coarsing pattern.

NO EVIDANCE OF SOLID OR CYSTIC LESSION seen.

INTRA HEPATIC BILLIARY RADICLES APPEARS TO BE normal .....

No irregular liver boarder seen.

Mid Axillary line liver Length...14 c m .and epigastric 10 c m ..

Gll Bladder :-

Gall Bladder visuелised in diff position and appears normal.

No Irregular bladder wall or calculas seen..

Kidney :-

Both kidney appears normal in size in shape and position.

No calculas or Hydro-nephrosis seen on either side.

Rt Kidney : 92 m m x 37 m m

Lt Kidney : 110 m m x 42 m m

Spleen seems to be in enlarged in size

left mid axilla lower

Pancreatic region appears normal .

U Bladder:- fills and appears normal..

No irregular bladder wall or calculas seen..

No Pleural effusion seen on either side.

No Ascites and/or free fluid seen in pelvis and in upper abdomen.

ADVISE :- Blood exam and follow up exam

Dr Krishnakant. S. Vaghela

To Mr. Nitesh Makand Chachay

Clinic : Ghansyam Bhuwan, Hospital Road, BHUJ (KUTCH) Ph. (H) 221509  
હોસ્પિટલ : ઘનશ્યામ ભુવન, હોસ્પિટલ રોડ, ભુજ (કચ્છ) મો. ૯૨૨૭૫ ૬૬૧૧૯, ૯૩૭૪૮ ૧૫૩૧૮



**SHRI KUTCHI LEVA PATEL EDUCATION & MEDICAL TRUST**  
**SANCHALIT**

**MATRUSHRI MEGHBAI PREMJI JETHA HOSPITAL & RESEARCH CENTRE**

SARDAR PATEL VIDYA SANKUL, BHUJ - MUNDRA ROAD, BHUJ-KUTCH. 370 001 TEL. : (02832) 231133, 231144

**Patient Name :** Nilesh Mukund Chauhan  
**Gender & Age :** Male 24 year 4 months  
**Ref. By Dr. :** Amina Khatri

**CR Number :** 0003870  
**Reg.Code :** 20100821247  
**Reg.Type :** OPD

**SONOGRAPHY ABDOMEN WITH PELVIS**

Prescribed Dt : 21-Aug-2010 10:59 am

**LIVER :**

Appears normal in size and shows altered echotexture. No evidence of focal or diffuse lesion.

No evidence of dilated IHBR. PV and CBD appear normal in calibre.

**GALL BLADDER :**

Appears normal. No evidence of stone or cholecystitis seen.

**PANCREAS :**

Appears normal in size and echotexture. No focal mass lesion or changes of pancreatitis seen.

**SPLEEN :**

Appears enlarged 12.6 cm in size and normal in echotexture. No evidence of focal or diffuse lesion.

**BOTH KIDNEYS :**

Appear normal in size and echotexture with preservation of corticomedullary differentiation. No evidence of calculus, hydronephrosis or mass lesion involving either kidney.

RK:9.8 x 4.3 cm LK: 10.4 x 4.5 cm

**URINARY BLADDER :**

appears normal. No intrinsic lesion seen.

**PROSTATE :**

normal in size and echotexture.

Size:3.5 x 3.0 x 2.6 cm. weight 14 gm.


No evidence of ascites or paraaortic lymphadenopathy.

**CONCLUSION :**

Altered echotexture of liver.

Boderline splenomegaly ( 12.6 cm).

**Advise:** Clinical correlation and further investigation.

  
**Dr. Mahesh S. Moradia**  
D.M.R.D.  
Radiologist

**Dr. Yogesh M. Gohil**  
M. D.  
Radiologist



27



**SHRI KUTCHI LEVA PATEL EDUCATION & MEDICAL TRUST  
SANCHALIT**

**MATRUSHRI MEGHBAI PREMJI JETHA HOSPITAL & RESEARCH CENTRE**

SARDAR PATEL VIDYA SANKUL, BHUJ - MUNDRA ROAD, BHUJ-KUTCH. 370 001 TEL.: (02832) 231133, 231144

**Patient Name** : Nilesh Mukund Chauhan  
**Sex & Age** : Male 24 year 4 months  
**Ref.Doctor** : Amina Khatri -

**CR Number** : 0003870  
**Reg.Code** : 20100821249  
**Reg.Type** : OPD

**Date** : 21-Aug-2010 11:01 am

Test	Result	Reference Range
------	--------	-----------------

**CBC with ESR**

**BLOOD VALUES**

HEMOGLOBIN **10.00** gm/dL 13.50 - 17.00 gm/dL  
Hb % **68.90** %

**TOTAL WBC COUNT**

TOTAL W.B.C. **4,200** /cmm 4000 - 11000 /cmm

**DIFFERENTIAL WBC COUNT**

POLYMORPHS **62** % 60 - 70 %  
LYMPHOCYTES **32** % 20 - 40 %  
EOSINOPHILS **3** % 1 - 6 %  
MONOCYTES **3** % 2 - 6 %  
BASOPHILS **0** % 0

**BLOOD INDICES**

RBC COUNT **4.46** millions/Cmm 4.5 - 5.5 millions/Cmm  
HCT **31** % 42 - 50 %  
MCV **70** fL 76 - 96 fL  
MCH **22** picogram 27 - 33 picogram  
MCHC **32** gm/dl 33 - 36 gm/dl  
RDW **16.70** % 11.5 - 14.5 %

**PLATELET COUNT**

PLATELET COUNT **108,000** /cmm 150000 - 450000/cmm  
E S R AFTER 1 HOUR **22** mm/hr 1 - 7 mm/hr

**PROTHROMBIN TIME**

**PROTHROMBIN TIME**

CONTROL **14.80** Seconds  
TEST **15.00** Seconds  
PROTHROMBIN INDEX **98.67** % 70 - 100 %  
T/C RATIO **1.014** .  
INR **1.000** .

Checked By :

Dr. Navin Patel (D.C.P., M.D. (PATHO))  
Pathologist