

“Chandan Kumar Sharma :- I used to get fever and swelling in my childhood. I got admitted in J. J. Hospital in March 2005. J. J. Hospital has done my biopsy of liver and sonography which showed liver failure.They operated me and removed my spleen but it could not help me my body swelling and fever kept on increasing.

On November 2005 I started Ayurvedic treatment of Dr Amina Khatri. I continued her treatment over a period of time I started improving my problems were solved.

Today I am healthy ok.

My present reports dated 18/02/2008 shows everything normal.

Thank you Dr. Amina M. Khatri



Chandankumar Sharma.

DR. AMINA'S

+ ROYAL AYURVEDA +

PURE AYURVEDIC TREATMENT

VISIT WITH PRIOR APPOINTMENT

Dr. Amina M. Khatri
(B.A.M.S.)
Mobile: - 094272 35572
Email: - draminakhatr@yahoo.com

3rd Floor, Near Hotel Ratrani,
Station Road, Bhuj - Kutch,
Gujarat, Pin- 370001. (India)
Tel:- 02832 226760

Date: 21/2/2008



चंदन कुमार शर्मा

चंदन कुमार शर्मा
उमर :- 72 साल
भुवनेश्वर

बचपन से मुझे कुरकार और बदन पे सङ्गण रहती थी. मार्च 2004 मे मे जे.जे. अस्पताल मे दाखिल हुआ। वहा सेनोग्राफी तथा लीवर बायोप्सी करवाने पर गाब्रूम वडा की मेरा लीवर फेल हुआ है। वहा ऑपरेशन करके मेरी वराल निकाल दे गई। परंतु मेरी तबीयत नही सुधरी। सङ्गण और कुरकार बढी गए।

जनवर 2004 से डॉ. आमीनाबेगम स्वामी की आयुर्वेदिक दवा शुरू की, तबीयत सुधरी गई। और अस्थि, अस्थि मेरी सारी कश्याद बंद हो गई। मे तंद्रुस ही बचा। 14/12/2004 मे मेरा सेनोग्राफी तथा स्त्रेण का रिपोर्ट नॉर्मल आया।

च्यवनपद डॉ. आमीना स्वामी

चंदन कुमार शर्मा

visit us : www.royalayurveda.com

Note: No other branch in world

Indian Cancer Society

Estd: 1951



Member representing India in U.I.C.C. [Association with WHO & CIOMS]
(The National Anti-Cancer Association)
(Recognised by the Government of India)

National Headquarters:
Lady Ratan Tata Medical &
Research Centre, M. Karve Road,
Cooperage, Mumbai 400 021.
Rehabilitation Centre,
74 Jerbai Wadia Road, Parel,
Mumbai 400 012.

MANAGING COMMITTEE:

DEPUTY CHAIRMAN

Dr. Suresh H. Advani
Director, Oncology,
Jaslok Hospital & Research Centre,
Asian Institute of Oncology

HON. SECRETARY:

(Managing Trustee)
Dr. Arun P. Kurkure
Consultant Oncologist,
Breach Candy Hospital,
Masina Hospital
Asian Institute of Oncology

JT. HON. SECRETARIES

Dr. Hosi Bhathena
Chief Plastic & Reconstructive Surgeon
Asian Institute of Oncology

Dr. Jagdeesh N. Kulkarni

Professor & Head,
Dept. of Genitourinary Oncology,
Asian Institute of Oncology,
Hon. Prof. Urologic Oncology,
Bombay Hospital Inst. of Medical Science,
Breach Candy Hospital

HON. TREASURER

Dr. Hemant B. Tongaonkar
Professor & Head,
Urologic & Gynaecologic Oncology,
Tata Memorial Hospital

FUND RAISING & CANCER AWARENESS SUB-COMMITTEE

Chairperson
Mrs. G. Jussawalla
Secretary
Ms. Diana Dawson

OFFICE OF THE MANAGING TRUSTEE

Personal	22872751 22047642
Administration & Accounts	22029941-2 22047436-9
Indian Journal of Cancer	22872746
Mobile Cancer Det. Unit	24125238
Bombay Cancer Registry	24122351
Rehabilitation Centre	24139445
Office of Director of Rehabilitation Centre	24156651 24161875
Parel Establishment	24151370

Appointment for Cancer
Check-Ups 22029941-2

Website:
www.indiancancersociety.org

Email: bcrics@vsnl.com

Fax: 24122351/24151771

FROM THE OFFICE OF THE HON. SECRETARY


HIST NO EE2962

DIAGNOSIS

LIVER BIOPSY - CHRONIC HEPATITIS ASSOCIATED WITH
MODERATE FIBROSIS

COMMENT

Based on Periseptal interface hepatitis and portal inflammation, a Knodell
Score of 2 is given to this biopsy.


DR. (MRS.) MANGALA R. SIMHA MD,DPB
BREACH CANDY HOSPITAL TRUST

Donations are exempt from Income Tax under Sec.35 and Sec. 80-G of the I.T. Act 1961.
Registered under the Societies Registration Act, 1860, No. 2983 of 1953-54 and the
Bombay Public Trusts Act, 1950, No. F-402 (Bom) of 1954.

DEPARTMENT OF RADIOLOGY & IMAGING

SIR J. J. GROUP OF HOSPITALS & GRANT MEDICAL COLLEGE
BYCULLA, MUMBAI-400 008.

ULTRASOUND EXAMINATION

Name : Chandantilakshmi Age : 7 yrs Date : 7/5/05
Ref. By : MM Hospital : JJH Sex : Male
Reg. No. :

ULTRASONOGRAPHY OF ABDOMEN

Liver : 12.5 cm coarse echotexture. NO focal lesion / I+BR
Portal vein : 9mm (N) . Coarse and Caliber.
CBD (N) coarse and Caliber
Gall Bladder : collapsed.
Pancreas not evaluated d/t excessive bowel gas.
Spleen : not visualised findings consistent w post-operative status.
Kidneys - Right : } (N) size shape echotexture. NO H+HUL Cal.
 Left : }
Bladder : partially distended hence
Pelvis : Pelvis not evaluated.

Miscellaneous : NO ~~abnormal~~ free fluid in abdomen and pelvis.

IMPRESSION : 7/5/05 (N) hepatomegaly w coarse echotexture. ~~no~~ co-rebate w LFT to upo level parenchymal disease

Examination performed by : Dr.

Signature :

S/DR smita
(SRI P. 2010)
S/DR. salil
(SRI P. 10)

**Shah Maishi Ghelabhai Gundalawala Kutchi Jain
Sarvodaya Kendra**

sanchalit

**The Bombay Dal Millers & Merchants Association
Sonography & X-ray Department**

122, Dr. Meisheri Road, Next to Dongri Market, Near Sandhurst Road Rly. Stn., Mumbai - 400 009.

Date : 25/01/2006
Name : MAST CHANDANKUMAR. Sex Male Age 11 Yrs
Ref. by : Dr. KHATRI.

USG ABDOMEN

USG ABDOMEN

- :Liver echotexture is coarse. Liver measures 11.2 cms.
S/o mild hepatomegaly.
- :CBD and Intra-hepatic Biliary radicals are normal in calibre.
- :Portal vein is normal in calibre.
- :Gall Bladder wall thickness is slightly increased. S/o cholecystitis.
- :Pancreas is normal in size and echotexture. No obvious focal lesion is seen.
- :Spleen is not visualised past history of splenectomy.
- :Rt Kidney measures 9.0 x 4.6 cms.
- :Lt Kidney measures 9.5 x 4.8 cms.
- :Both the Kidneys are normal in size and echotexture. There is no evidence of calculus / hydronephrosis in both the kidneys.
Cortico-Medullary differentiation is well maintained in both the Kidneys
- :Urinary Bladder is well distended. There is no evidence of calculus/ mass in it.
- :Prostate is normal in size and shows normal echotexture. No obvious focal lesion seen.
- :No evidence of any retroperitoneal lymphadenopathy noted.
- :No ascites or pleural effusion seen.



**Shah Malshi Ghelabhai Gundalawala Kutchi Jain
Sarvodaya Kendra**

sanchalit

**The Bombay Dal Millers & Merchants Association
Sonography & X-ray Department**

122, Dr. Meisheri Road, Next to Dongri Market, Near Sandhurst Road Rly. Strn., Mumbai - 400 009.

Phone : 2370 0064



IMPRESSION : MILD HEPATOMEGALY WITH COARSE ECHOTEXTURE.
: CHOLECYSTITIS.
: CORRELATE CLINICALLY.

DR. S.M. DAIMI.

D.M.R.D.
Consultant Radiologist.



**Shah Malshi Ghelabhai Gundalawala Kutchi Jain
Sarvodaya Kendra**

sanchalit

**Smt. Arunaben Navinchandra Thakershi Visaria
Pathology Department**

122, Dr. Meisheri Road, Next to Dongri Market, Near Sandhurst Road Rly. Strn., Mumbai - 400 009.

Phone : 2370 0064
2377 0108



Date : 18/02/2008
Lab No : 24
Name : Mast.Chandan Sharma. Male
Ref. by : Dr.

COMPLETE BLOOD COUNT & ESR

Test	Result	Units	Normal Range
<u>Haemoglobin</u>	13.4	gm/dl	13.5 - 18
R.B.C. Count	3.91	$\times 10^6/c.mm$	4.6 - 6.2
Haematocrit	37.6	%	40 - 54
M.C.V	96.0	fl	76 - 96
M.C.H.	34.2	pg	27 - 32
M.C.H.C.	35.6	%	32 - 36
<u>Total W.B.C. Count</u>	25,800	/c.mm	4000 - 10900
<u>Differential Count</u>			
Neutrophils	50	%	40 - 75
Lymphocytes	49	%	20 - 45
Eosinophils	01	%	1 - 6
Basophils	00	%	upto 1
Monocytes	00	%	upto 8
Abnormalities in W.B.C.'s	Nil		
Abnormalities in R.B.C.'s	Nil		
PLATELET COUNT	2,91,000	/cmm	150000 - 450000
Platelets	Adequate on smear		
Malarial Parasites	Absent		
<u>E.S.R.</u>	10	mm at 1 hour	0 - 15

DONE ON FULLY AUTOMATED HEMA STAR II

A

DR. KETAN CHHEDA
M.D. PATHOLOGIST.

**Shah Malshi Ghelabhai Gundalawala Kutchi Jain
Sarvodaya Kendra**

sanchalit

**The Bombay Dal Millers & Merchants Association
Sonography & X-ray Department**

122, Dr. Meisheri Road, Next to Dongri Market, Near Sandhurst Road Rly. Strn., Mumbai - 400 009.

Reg.Date : 18/02/2008

Date : 21/02/2008

Name : MAST.CHANDAN SHARMA.

Sex Male Age 12 Yrs

USG ABDOMEN

USG ABDOMEN

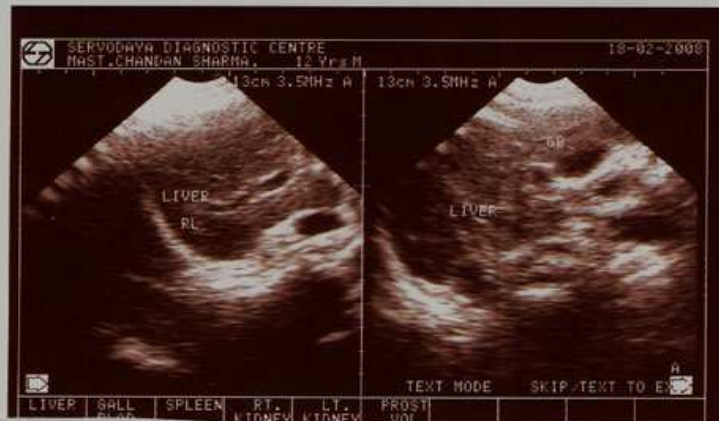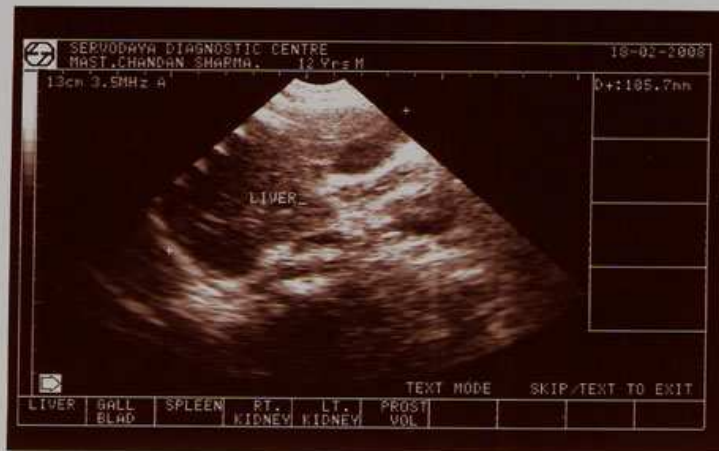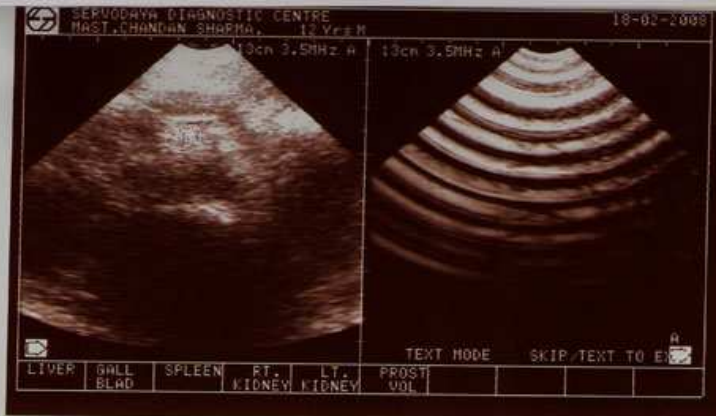- :Liver is normal in size and echotexture. There is no evidence of any focal/diffuse lesion.
- :CBD and Intra-hepatic Biliary radicals are normal in calibre.
- :Portal vein is 11 mm in calibre.
- :Gall Bladder is well distended. There is no e/o any calculus/mass in it.
- :Pancreas is normal in size and echotexture. No obvious focal lesion seen
- :Spleen is not visualised. P/H/O SPLENECTOMY.
- :Rt Kidney measures 8.2 x 4.6 cms.
- :Lt Kidney measures 8.8 x 5.0 cms.
- :Both the Kidneys are normal in size and echotexture. There is no evidence of calculus / hydronephrosis in both the kidneys.
Cortico-Medullary differentiation is well maintained in both the Kidneys
- :Urinary Bladder is well distended. There is no e/o calculus/mass in it.
- :No evidence of any retroperitoneal lymphadenopathy noted.
- :No ascites or pleural effusion seen.

IMPRESSION : NORMAL USG ABDOMEN.

(POST SPLENECTOMY STATUS)

DR. S.M. DAIMI.

D.M.R.D.
Consultant Radiologist.



Phone : 2370 0064
2377 0108

**Shah Malshi Ghelabhai Gundalawala Kutchi Jain
Sarvodaya Kendra**

sanchalit

**Smt. Arunaben Navinchandra Thakershi Visaria
Pathology Department**

122, Dr. Meisheri Road, Next to Dongri Market, Near Sandhurst Road Rly. Stn., Mumbai - 400 009.

Date : 18/02/2008
Lab No : 24
Name : Mast.Chandan Sharma. Male
Ref. by : Dr.

PROTHROMBINE TIME

Test	Result	Units	Normal Range
Prothrombin Time : Test	14.00	sec	
Prothrombin Time : Control	13.00	sec	
Test / Control	1.08		
Control / Test (Index)	92.86		
I.S.I Value	1.50		
I.N.R Value	1.12		

Dr. Ketan
DR. KETAN CHHEDA
M.D. PATHOLOGIST.